

A technique for repairing a removable partial denture attachment anchor

Hai Zhang, DMD, PhD,^a and Joseph E. Grasso, DDS, MS^b

School of Dentistry, University of Washington, Seattle, Wash; School of Dental Medicine, University of Connecticut Health Center, Farmington, Conn

Overdenture attachments have been extensively used to improve retention, stability, and function of removable prostheses, supported either by retained roots or strategically placed endosseous implants.^{1,2} Ball retentive anchors are commonly used systems.³ These ball systems come in a wide range of dimensions and retentive matrix materials. As a result, interocclusal and facial space are critical clinical factors when selecting the desired ball anchor and its retentive matrix,⁴ factors which are frequently overlooked. Sufficient interocclusal space is necessary to accommodate the height of the ball anchor, the retentive matrix housing seated onto the anchor, and the space over the matrix housing to allow a sufficient thickness for the retention of the tooth or teeth on the prosthesis.

There are times when interocclusal space deficiency may not be recognized until well into the treatment process. If the anchor is supported by an implant, the problem may be solved by simply replacing the anchor with a different dimension or configuration. However, adjustment of inadequate available space may be difficult if the treatment involves a retained root with a cemented dowel. The risk of root fracture does exist when attempting to remove a cemented dowel with an attached ball anchor.⁵

The presented procedure offers a solution to insufficient interocclusal space in a failed treatment of a removable partial denture (RPD) supported by a ball retentive anchor attached to a cast dowel cemented in a retained root. A 38-year-old woman received a Kennedy Class I maxillary removable partial overdenture replacing the left lateral incisor, bilateral canines, and all posterior teeth. The RPD was retained by 2 ball anchors. One ball anchor, of unknown manufacturer, was incorporated in a cast dowel and coping in the maxillary right canine position on an endodontically treated root. The other was a ball retentive anchor supported by an endosseous implant (ITI; Institut Straumann AG, Waldenburg, Switzerland) in the maxillary left first premolar position. The patient returned repeatedly to have the denture repaired because of insufficient interocclusal space resulting in fracture at the maxillary right canine

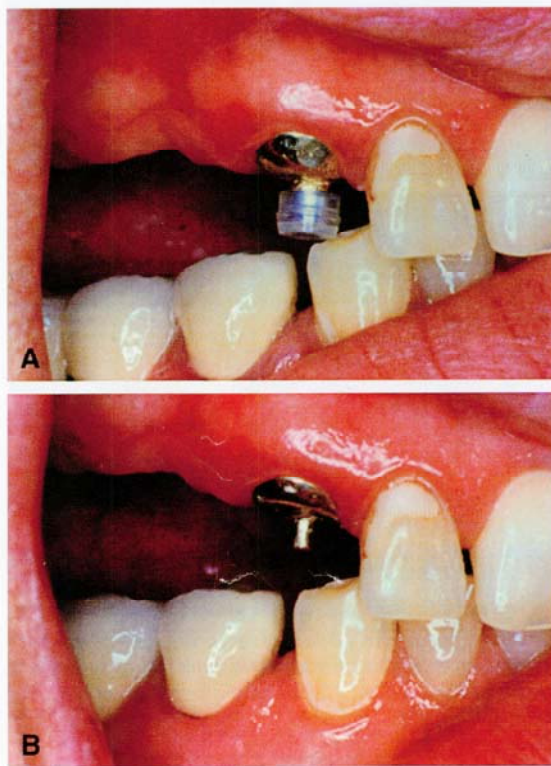


Fig. 1. A, With matrix in place, space was deficient. B, Adjustment of previous matrix and base of dome to gain more space.

position. There was insufficient acrylic resin to accommodate the retentive housing, causing weakness of the denture (Fig. 1, A). Removal of the cast dowel was considered, but because of the length of the dowel, it was not removed for fear of root fracture. The treatment of choice was to replace the existing ball anchor with a repair ball anchor (Rhein'83, Bologna, Italy). With the kit provided by the manufacturer, it was possible to accomplish this chairside.

PROCEDURE

1. Recontour the existing ball anchor to the shape of a cylinder (approximately 2.5 mm in height and 1 mm in diameter), and move the dome portion apically by using a high-speed handpiece and diamond

^aAssistant Professor, Department of Restorative Dentistry, University of Washington.

^bProfessor, Department of Prosthodontics and Operative Dentistry, University of Connecticut Health Center.

J Prosthet Dent 2005;94:299-300.

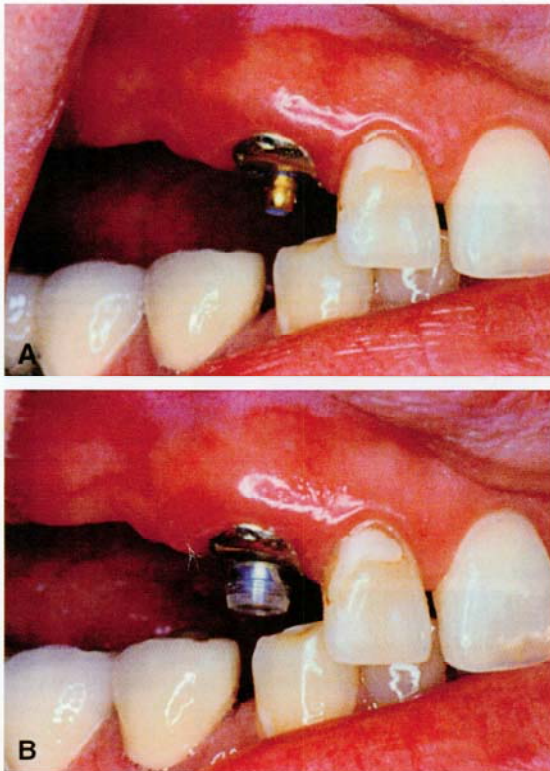


Fig. 2. A, Cementation of ball anchor using resin cement. B, Additional space was gained by this procedure. Matrix was placed and ready to be transferred with autopolymerizing acrylic resin.

rotary cutting instrument (Cat. # 8836KR.314.016; Brasseler USA, Savannah, Ga) with copious water.

2. Evaluate the height of the reshaped metal ball anchor to ensure sufficient space for a new ball anchor, retentive matrix, and thickness of acrylic resin to support the replaced tooth. Polish the dome surface with rubber points (Shofu, San Marcos, Calif) (Fig. 1, B).
3. Under an isolated dry field, cement the Rhein repair ball anchor onto the reshaped ball anchor using autopolymerizing resin cement (Bistite SC; J Morita USA, Inc, Irvine, Calif) (Fig. 2, A).
4. Remove the excessive cement. Transfer the nylon matrix intraorally using a conventional method (Fig. 2, B).⁶
5. Perform occlusal adjustment with articulating paper, followed by polishing the repaired denture in the traditional manner.

REFERENCES

1. Jemt T, Chai J, Harnett J, Heath MR, Hutton JE, Johns RB, et al. A 5-year prospective multicenter follow-up report on overdenture supported by osseointegrated implants. *Int J Oral Maxillofac Implants* 1996;11:291-8.
2. Naert I, Gizani S, Vuylsteke M, Van Steenberghe D. A 5-year prospective randomized clinical trial on the influence of splinted and unsplinted oral implants retaining a mandibular overdenture: prosthetic aspects and patient satisfaction. *J Oral Rehabil* 1999;26:195-202.
3. Burns DR. Mandibular implant overdenture treatment: consensus and controversy. *J Prostodont* 2000;9:37-46.
4. Stamos DE, Gutmann JL. Survey of endodontic retreatment methods used to remove intraradicular posts. *J Endod* 1993;19:366-9.
5. Morrow RM, editor. *Dental laboratory procedures: complete dentures*. Vol 1. 2nd ed. St. Louis: Mosby; 1985. p. 312-24.
6. Brewer AA, Morrow RM. *Overdentures*. 2nd ed. St. Louis: Mosby; 1980. p. 231-2.

0022-3913/\$30.00

Copyright © 2005 by The Editorial Council of *The Journal of Prosthetic Dentistry*.

doi:10.1016/j.prosdent.2005.06.003